

Micro-CT User Meeting 2014

Paper Title:

Ex vivo experimental model for percutaneous vertebroplasty: microCT utility

Presenting Author:

Lucena, Sónia

Organization:

University of Évora

Address:

Universidade de Évora
Departamento de Medicina Veterinária
Pólo da Mitra, ap 94
7002-554 Évora

E-mail:

slucena@uevora.pt

Choice of presentation: (highlight the type you prefer)

Oral Presentation X

-

Poster Presentation

Ex vivo experimental model for percutaneous vertebroplasty: microCT utility

Lucena S^{1,2*}, Oliveira, MT^{1,2*}, Potes JC^{1,2}, Queiroga MC^{1,2}, Reis JC^{1,3}

¹ Veterinary Medicine Department, School of Science and Technology, University of Évora, Évora, Portugal slucena@uevora.pt

² Institute of Mediterranean Agricultural and Environmental Sciences (ICAAM), University of Évora, Évora, Portugal

³ Centre in Research for Ceramics & Composite Materials (CICECO), University of Aveiro, Aveiro, Portugal

*Both authors contributed equally to this work

Aims

The aim of this study was to develop an *ex vivo* experimental animal model for percutaneous vertebroplasty, for further application *in vivo* to test novel bone injectable cements.

Percutaneous vertebroplasty is a surgical minimally invasive procedure and is frequently required for human surgical treatment of vertebral compression fractures, an age related pathology that causes pain and limitations to daily activities (1, 2, 3, 4). This technique consists on a cement injection into the vertebral body allowing a significant pain relief with associated improvement in daily life performance (5).

Sheep is becoming the animal of choice for testing vertebral implants because this species is readily available and show great homogeneity when selected for age, breed, and sex (6, 7, 8, 9). Due to similar volume and size of its vertebrae compared to humans is possible to use identical implants and instruments as performed under clinical conditions. The biomechanical behaviour of ovine lumbar spine was found to be qualitatively similar to that of human specimens (7). Moreover, bone formation rates in sheep are similar to those in humans (10). One limitation of this animal model is the relatively high bone mineral density and the hard cortical bone of ovine lumbar vertebrae compared to osteoporotic human vertebrae (7).

Prior to live surgery experiments, the development of an animal vertebral bone defect model and feasibility evaluation of the model with bioactive injectable bone cement is needed (11).

For percutaneous vertebroplasty an entry point is made in the tissue and vertebra instead of performing an incision along the lumbar spine (7). The transpedicular approach, the most often used technique for humans percutaneous vertebroplasty, can be performed unilaterally or bilaterally (12). Safety of transpedicular approach relies on restricting the instruments to the pedicle bony confines until the vertebral body is entered, with a relatively restricted trajectory to the vertebral body. With anterior posterior and lateral fluoroscopy views of the target vertebral body, the approach follows the slightly inferior and medial orientation of the pedicle followed anteriorly; this trajectory is followed through the back's soft tissues and maintained in the pedicle (12).

Although the lumbar facet joints and pedicles of quadrupeds are oriented at an angle of less than 30° to the frontal plane (compared to over 60° in humans) the pedicles are relatively short and sagittally oriented. Therefore, according to Benneker *et al.* (2012) to achieve a safe central needle placement, the transition between the transverse process and the pedicle is the ideal entry point, aiming towards the cranial and caudal hemivertebra in a 45° orientation to the frontal plane, through a trans- to parapedicular approach. However, in 19 of the 33 specimens studied, cement leakage into the spinal canal was observed at the end of the cement injection,

which is undesirable for an *in vivo* study; as this was a terminal study set-up, no clinical abnormalities could be documented.

Zhu *et al.* (2011) performed other sheep vertebral model with bone defect (6.0 mm in diameter and 15 mm in depth). In this study, four vertebrae groups were drilled perpendicularly to the center of the sagittal plane of vertebral bodies by different diameter drills (Ø2.0 mm; Ø4.0 mm; Ø6.0 mm; Ø8.0 mm). The vertebral model bone defect was replicable and effective for assessing injectable bioactive bone substitutes in vertebral reconstruction. Nevertheless, this study used a conventional surgical access with incision through skin and muscle.

MicroCT scans have been previously used to estimate the position of the needle and insertion depth by observation of the corresponding images and then to drill holes at the appropriate positions to guide needle insertion (13). MicroCT analysis has been used for many years to quantify trabecular bone morphology and it can be applied also to scan defect regions *in vivo* using new generation live animal scanners (14). When used for bone analysis, the retrieved samples remain available for posterior histological evaluation or biomechanical testing because microCT has the advantage of being non-destructive, providing a detailed assessment of vertebral bone architecture morphological parameters and structural characteristics which can be used to assess form and function (15).

It seems essential to develop an *ex vivo* experimental animal model for vertebroplasty, bearing in mind the feasibility of a percutaneous approach and the absolute need to avoid cement leakage into the spinal canal. Only possible if a suitable defect is performed which may be accurately confirmed using a MicroCT.

Method

Ex-vivo studies were carried out in 30 ovine lumbar vertebrae (10 L4, 10 L5 and 10 L6), from 10 mature Merino sheep, previously frozen at -20°C for 48h and then stripped of soft tissue and disarticulated. To fit in the microCT, vertebrae were cut through the spinous and transverse processes. Vertebral foramina remained intact. All vertebrae underwent a μ CT analysis (Skyscan 1174, Bruker, Belgium) prior to the execution of the defects. Six vertebrae remained intact and the others 24 were placed and fixed on a radiolucent table in ventral recumbency. All defects were created in the cranial hemivertebrae under fluoroscopic guidance and tactile control. Two defects were created bilaterally in the vertebral bodies with a dorsolateral cortex entrance. The chosen access point was between the pedicles and transverse processes of each vertebra, considering that the instrumentation of the pedicle always carries the risk of fracture to the pedicle and the risk of vertebral foramina disruption; these risks are doubled with a bipedicular approach. Moreover, with this approach only a limited access angle was possible and defects would be smaller and not connected.

An osteo introducer system (Kyphon, Medtronic Spine LLC, Portugal, Ref. T05E) was used. A blunt osteo introducer stylet (Ø 3,5 mm) inside a cannula (Ø 4 mm) was placed between the pedicles and transverse processes of each vertebra to access manually the cortical bone of the ovine vertebrae and to perform the entrance hole. Then the blunt osteo introducer stylet was removed and a precision manual drill (Ø 3,35 mm) was advanced inside the cannula with an orientation of 30°-50° regarding a transverse plane and 0°-30° regarding the frontal plane, towards the centre of the cranial hemivertebrae. Bone debris was removed from the defects. A second μ CT analysis was then performed.

The relatively high trabecular bone density and the hard cortical bone of ovine lumbar vertebrae are features which hampered the creation of the defect. Furthermore clearing the defects of any residual debris may be difficult and the large lumbar vertebrae nutritional foramina are a surgical limitation. Vertebral and nutritional foramina must remain intact otherwise animals die or neurologic complications after the surgical procedure may occur due

to ischemia, compression and embolism. In vertebrae caudal to L5 lumbar vertebrae, problems arose due to short vertebral bodies.

A 2D and 3D scan images analysis provides detailed information of vertebral bone architecture, morphological parameters and structural characteristics which can be used to assess its form and function. Therefore, with microCT images adverse anatomical features for this study could be overcome and decisions about defects entry points and vertebral body angles orientation were safely taken.

Each scan comprises 906 cross-sections and an oversize scan was needed for all samples. Scans were performed with an 1mm aluminum filter, 50 KV, 800 μ A, pixel size of 62,08, exposure time of 2200, rotation step of 0,8°, full rotation of 360° and 2 average frames per image were used. The vertebrae were reconstructed in NRecon software (Skyscan, Bruker, Belgium) and ROI were determined in CTAn (Skyscan, Bruker, Belgium). Uniform threshold method was used.

To calculate the volume of interest (VOI), the appropriate region of interest (ROI) was manually determined in every 10 cross-sections between the top and bottom of the selected region. Only the defect region was considered including bone debris. A VOI 3D analysis is required to predict the amount of injectable bone cement inside the defect.

For the descriptive statistics analysis SPSS 20 programme was used ($p \leq 0,05$).

Results

The mean total VOI volume for vertebral body defects was 1209,04 mm³ with a 226,45 standard deviation. The results of descriptive statistics analysis are shown in table 1.

Table 1: Descriptive statistics analysis for vertebral body defects total VOI volume (n=24)

	N	Minimum (mm ³)	Maximum (mm ³)	Mean (mm ³)	Std. Deviation
lumbar vertebrae (L4,L5,L6)_sheep	24	748,40	1618,60	1209,0417	226,45003
Valid N (listwise)	24				

Figures 1 and 2 show the scan images and the 3D reconstructed images of sheep mature lumbar vertebrae (L4). The large nutritional vertebral foramina were one of the surgical procedure limitations.

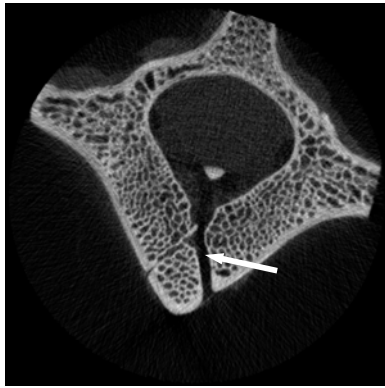


Figure 1: Scan image of a lumbar vertebra showing the L4 nutritional foramen of a mature sheep (white arrow).



Figure 2: A 3D reconstructed image of a lumbar vertebra showing the L4 nutritional foramen of a mature sheep (white arrow).

Figures 3 and 4 show the defects created in sheep mature lumbar vertebrae (L6). Dataset scan images and 3D reconstructed images clearly indicate that the defects are interconnected and reproducible defects were achieved.

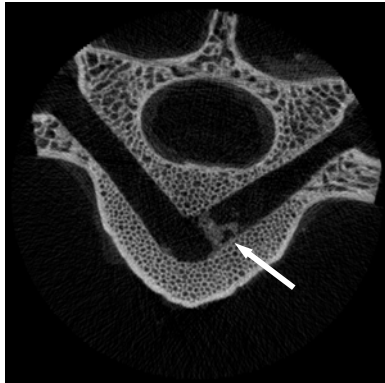


Figure 3: Scan image of a lumbar vertebra (L6) from a mature sheep showing the defect with bone debris included (white arrow).



Figure 4: A 3D reconstructed image of a lumbar vertebra (L6) from a mature sheep showing the body defect (white arrow).

Conclusion

Ex vivo experimental model was successfully reproduced and the defects were interconnected. MicroCT was a fast fundamental image tool that provided important

information for surgical procedures and their limitations, and has the advantage of being non-destructive.

Scans and 3D reconstructed images were useful to decide the exact location of the access point and to correct the angle orientation to reach the vertebral body. This methodology also allows performing defects with no disruption of the cortical bone on the vertebral body and vertebral and nutritional foramina. Moreover, the presence of unremoved small amounts of bone can be identified by those images.

Acknowledgements

This research project has been supported by the European Commission under the 7th Framework Programme through the project Restoration, under the action "Collaborative project targeted to SMEs", grant agreement NMP.2011.2.1-1.

The support from Medtronic Spine LLC Company, Portugal is gratefully acknowledged for supplying surgical material (Osteo Introducer® System).

References:

1. Oleksik AM, Ewing S, Shen W, Van Schoor NM, Lips P. "Impact of incident vertebral fractures on health related quality of life (HRQOL) in postmenopausal women with prevalent vertebral fractures". *Osteoporosis international* 16(8), 861-70, 2005.
2. Suzuki N, Ogikubo O, Hansson T. "The course of the acute vertebral body fragility fracture: its effect on pain, disability and quality of life during 12 months". *Eur Spine J* 17(10), 1380-1390, 2008.
3. Syed M, Solomon J, Patel NA, Shaikh A. "Percutaneous vertebroplasty". *JIMA* 37, 54-58, 2005.
4. Serra L, Kerami FM, Panagiotopoulos K, De Rosa V, Vizioli L. "Vertebroplasty in the treatment of osteoporotic vertebral fractures: results and functional outcome in a series of 175 consecutive patients". *Minim Invasive Neurosurg* 50(1), 12-7, 2007.
5. Layton KF, Thielens KR, Koch CA, *et al.* "Vertebroplasty, first 1000 levels of a single center: evaluation of the outcomes and complications". *AJNR* 28(4), 683-689, 2007.
6. Kobayashi N, Ong K, Villarraga M, Schwardt J, Wenz R, Togawa D, Fujishiro T, Turner S, Seim HB, Bauer TW. "Histological and mechanical evaluation of self-setting calcium phosphate cements in a sheep vertebral bone void model". *Journal of Biomedical Materials Research Part A* 81, 838-846, 2007.
7. Benneker LM, Gisepe A, Krebs J, Boger A, Heini PF, Boner V. "Development of an *in vivo* experimental model for percutaneous vertebroplasty in sheep". *Vet Comp Orthop Traumatol* 25, 173-177, 2012.
8. Benneker LM, Krebs J, Boner V, Boger A, Heini PF, Gisepe A. "Cardiovascular changes after PMMA vertebroplasty in sheep: the effect of bone marrow removal using pulsed jet-lavage". *Eur Spine J* 19, 1913-1920, 2010.
9. Potes JC, Reis JC, Capela e Silva F, Relvas C, Cabrita AS and Simões AJ. "The sheep as an animal model in orthopaedic research". *Experimental Pathology and Health Sciences* 2 (1), 29-32, 2008.
10. Vadalà G, De Strobel F, Bernardini M, Denaro L, D'Avella D and Denaro V. "The transpedicular approach for the study of intervertebral disc regeneration strategies: *in vivo* characterization". *Eur Spine J.*, 2013. DOI 10.1007/s00586-013-3007-y.
11. Zhu X.S, Zhang Z M, Mao H Q, Geng D C, Zou J, Wang G L, Zhang Z G, Wang J H, Chen L and Yang H L. "A novel sheep vertebral bone defect model for injectable bioactive vertebral augmentation materials". *J Mater Sci: Mater Med* 22, 159-164, 2011.
12. Ringer AJ and Bhamidipaty SV. "Percutaneous Access to the Vertebral Bodies: A Video and Fluoroscopic Overview of Access Techniques for Trans-, Extra-, and Infrapedicular Approaches". *World Neurosurg* 80 3/4, 428-435, 2013.

13. Tarsuslugil SM, O'Hara RM, Dunne NJ, Buchanan FJ, Orr JF, Barton DC and Wilcox RK. "Development of calcium phosphate cement for the augmentation of traumatically fractured porcine specimens using vertebroplasty". *Journal of Biomechanics* 46, 711–715, 2012.
14. Guldberg RE, Duvall CL, Peister A, Oest ME, Lin ASP, Palmer AW, Levenston ME. "3D imaging of tissue integration with porous biomaterials". *Biomaterials* 29, 3757–3761, 2008.
15. Hulme PA, Ferguson SJ, Boyd SK. "Determination of vertebral endplate deformation under load using micro-computed tomography". *Journal of Biomechanics* 41, 78–85, 2008.